



Review

Transport for language south of the Sylvian fissure: The routes and history of the main tracts and stations in the ventral language network



Claude J. Bajada, Matthew A. Lambon Ralph^{*} and Lauren L. Cloutman^{*}

Neuroscience and Aphasia Research Unit (NARU), School of Psychological Sciences, The University of Manchester, UK

ARTICLE INFO

Article history:

Received 27 January 2015

Reviewed 26 April 2015

Revised 7 May 2015

Accepted 11 May 2015

Action editor Stefano Cappa

Published online 19 May 2015

Keywords:

White matter

Language

Semantics

Ventral pathway

Temporal lobe

ABSTRACT

It is now ten years since a 'ventral language pathway' was demonstrated *in vivo* in the human brain. In the intervening decade, this result has been replicated and expanded to include multiple possible pathways and functions. Despite this considerable level of research interest, age-old debates regarding the origin, course, termination and, indeed, the very existence of the tracts identified still remain. The current review examines four major tracts associated with the ventral 'semantic' language network, with the aim of elucidating and clarifying their structural and functional roles. Historical and modern conceptualisations of the tracts' neuroanatomical origins and terminations will be discussed, and key discrepancies and debates examined. It is argued that much of the controversy regarding the language pathways has resulted from inconsistencies in terminology, and the lack of a white matter 'lingua franca'.

© 2015 The Authors. Published by Elsevier Ltd. This is an open access article under the CC BY-NC-ND license (<http://creativecommons.org/licenses/by-nc-nd/4.0/>).

1. Introduction

Due to the recent advances in neuroimaging methodologies such as diffusion tensor imaging (DTI) and MR tractography, the clinical and cognitive neuroscience community has become increasingly interested in the anatomy of brain connection; that is, the white matter pathways of the brain as well as their disconnection in neurological conditions. A key principle underlying this interest is the conceptualisation of the brain as a functionally-integrated yet neutrally-

distributed system, with white matter tracts allowing information to be exchanged, manipulated and integrated rapidly between distant brain regions. Alongside neuropsychological (Butler, Lambon Ralph, & Woollams, 2014; Patterson & Lambon Ralph, 1999), transcranial magnetic stimulation (Holland & Lambon Ralph, 2010; Pobric, Jefferies, & Lambon Ralph, 2007) and functional neuroimaging studies (Hickok & Poeppel, 2004, 2007; Scott, Blank, Rosen, & Wise, 2000), such *in vivo* explorations of white matter connectivity have catalysed a reconsideration of the distributed neural

^{*} Corresponding authors. Neuroscience and Aphasia Research Unit (NARU), School of Psychological Sciences (Zochonis Building), University of Manchester, Brunswick Street, Manchester, M13 9PL, UK.

E-mail addresses: matt.lambon-ralph@manchester.ac.uk (M.A. Lambon Ralph), lauren.cloutman@manchester.ac.uk (L.L. Cloutman). <http://dx.doi.org/10.1016/j.cortex.2015.05.011>

0010-9452/© 2015 The Authors. Published by Elsevier Ltd. This is an open access article under the CC BY-NC-ND license (<http://creativecommons.org/licenses/by-nc-nd/4.0/>).

network for language (Parker et al., 2005; Saur et al., 2008, 2010). Accordingly, the resultant theories and hypotheses have moved away from Geschwind's single pathway 'dorsal-only' model towards a dual-pathway architecture; a notion that can be found in the classical neurological literature (Weiller, Bormann, Saur, Musso, & Rijntjes, 2011) and provides the basis for contemporary neurocomputational models of language processing (Bornkessel-Schlesewsky & Schlesewsky, 2013; Bornkessel-Schlesewsky, Schlesewsky, Small, & Rauschecker, 2015; Ueno & Lambon Ralph, 2013; Ueno, Saito, Rogers, & Lambon Ralph, 2011).

Over and above the theoretical importance of the ventral route, there has been a rapidly-increasing interest in correlating neurological dysfunction to damaged tracts. This is a positive step since it moves away from a strict localisationist symptom to anatomy correlation and moves toward thinking of neural dysfunction as a result of damage to a highly interconnected system, reminiscent of Wernicke's approach and Geschwind's emphasis of disconnection syndromes (Eggert, 1977; Geschwind, 1970). Damage to the white matter tracts of the temporal lobe have been correlated with many psychiatric and neurological conditions. For example, schizophrenia has been associated with abnormalities of the uncinate (UF), inferior fronto-occipital (IFOF) and inferior longitudinal (ILF) fasciculi (Catani et al., 2012; Fujino et al., 2014; Liu et al., 2013), while depression has also been found to correlate with abnormal fractional anisotropy in the UF (Aghajani et al., 2013). Patients with fronto-temporal dementias (e.g., semantic dementia) have extensive temporopolar white matter thinning including reduction of connected white matter tracts (e.g., UF, ILF and arcuate fasciculus – AF) outside the traditional rostral temporal areas that semantic dementia is known to affect (Acosta-Cabronero et al., 2011). Damage to the left IFOF and UF due to stroke have also been associated with poor performance on semantic tasks (Han et al., 2013), whilst damage to the AF correlates with impaired repetition (Fridriksson et al., 2010). However, it may not be sufficient to correlate disorders/symptoms with white matter lesions. In order to understand the complexity of highly interconnected brain systems, one can look towards network science (Rubinov & Sporns, 2010; Sporns, 2013) in order to understand how damage to one area may affect the whole network. In this way anatomical knowledge of the whole system may help improve diagnosis and prognosis predictions in patients with neurological and psychiatric conditions.

The current review examines four key tracts of the temporal lobe that have been associated with the ventral language pathway (see Fig. 1). The literature reveals controversy over both the structure and the function of each tract. Regarding anatomy, there is considerable debate over the tracts' exact course and their precise termination points. Regarding function, many researchers classify these tracts as central to the ventral semantic language network (Duffau, Herbet, & Moritz-Gasser, 2013; Ueno & Lambon Ralph, 2013; Ueno et al., 2011), although they have also been implicated in visual processing (Bagga et al., 2013; Tusa & Ungerleider, 1985), emotional processing (Williamson, Heilman, Porges, Lamb, & Porges, 2013) and cognitive control (Harvey, Wei, Ellmore, Hamilton, & Schnur, 2013).

2. Methodological considerations

Before considering the key temporal lobe tracts, it is important to briefly examine the four key methods used to evaluate structural connectivity: 1) tracer studies; 2) gross dissection; 3) polarised light imaging (PLI) and 4) diffusion MRI tractography. All four methodologies have their own relative strengths and limitations, and it is important to remember that no one method can provide the ground truth about the brain's white matter architecture.

Long considered the gold standard for white matter tracing, neural tracer studies inject a marked tracer (e.g., a virus or protein) into a region of the brain and wait for it to propagate along the connected axons to its cortical origin or termination points. The tracer's movement is established post mortem, revealing very precise information about neural pathways. Despite their precision, however, tracer studies suffer from three main limitations. Most importantly, due to ethical considerations, tracer work must be done in non-human animals, hence human inferences from tracer studies must be made with extreme caution. This is an issue of no small importance when considering the neural network underpinning language, a uniquely human cognitive skill. Secondly, tracer studies require strong prior anatomical knowledge regarding where to inject the tracer and where in the brain to anticipate the origin/termination points will be. Finally, although precise, the number of injections per specimen is very small and thus only a minimal proportion of the total area within a single brain can be sampled.

Gross dissection, on the other hand, can be carried out on human brains. The most common approach adopted is the Klingler method (Agrawal et al., 2011; Ludwig & Klingler, 1956) in which a fixed brain is first frozen to encourage fracturing along the white matter tracts and then carefully dissected in order to reveal the location, divisions and course of each tract. Whilst providing a definitive method for establishing target tracts in human brains, these methods suffer from the facts that they are performed ex-vivo, samples are very scarce and, since it is a destructive method, replication on the same brain is impossible. In addition, given that grey matter has to be removed in order to reveal the underlying white matter pathways, it becomes difficult to establish the cortical terminations of each tract. Finally, freezing a fixed brain makes it fragile, thus dissection requires great skill and expertise, and accurately following the white matter path particularly at points of forking or cross-fibres is non-trivial and can potentially be influenced by the researcher's prior expectations.

Three-dimensional PLI is an optical imaging method which takes advantage of the birefringent properties of the myelin surrounding neuronal axons, enabling ultra-high resolution white matter tract reconstruction from gross histological brain sections (Larsen, Griffin, Grassel, Witte, & Axer, 2007). In this technique, ex-vivo brains are first fixed, frozen and sliced using a cryostat microtome to a thickness of approximately 100 µm thick (or thinner). Different angles of polarised light are then shone upon the sections and the sections are repeatedly imaged. From these multiple images, the orientation of the nerve fibre within each slice can be calculated, and the resulting fibre orientation maps compiled to produce 3D

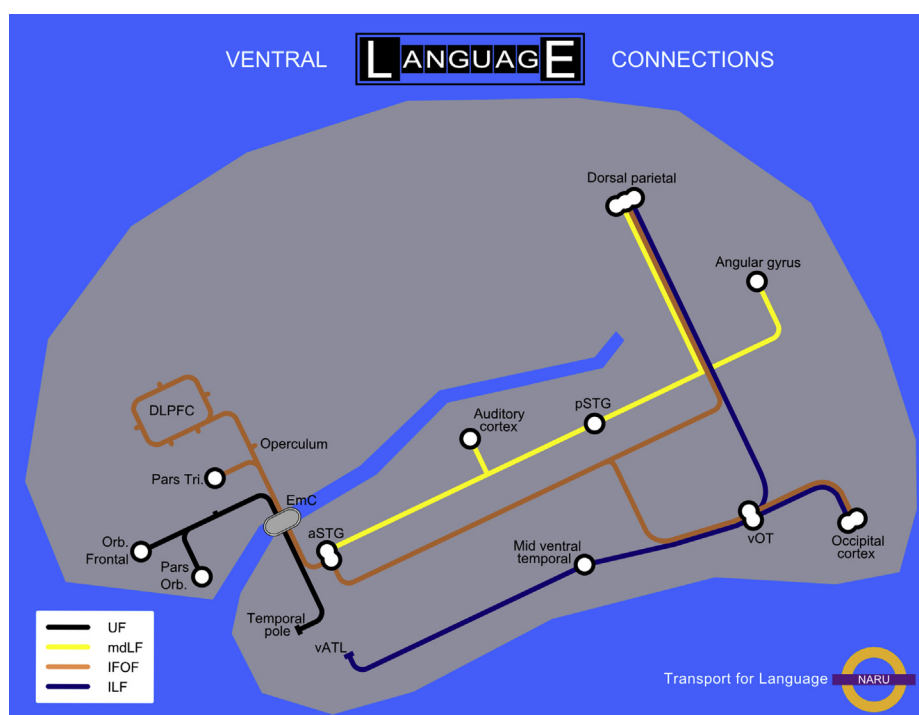


Fig. 1 – A representation of the ventral language network showing the four main fibre tracts, their relative routes and their terminations.

fibre models of key tracts (Axe, Amunts, et al., 2011). The two main advantages of PLI are its very high resolution (at the sub-millimetre scale), and its direct measurement of neuronal fibres (as opposed to the indirect measurement inherent in diffusion imaging). As such, this technique has the potential to resolve some neuroanatomical questions that are unanswerable using methods like diffusion MRI (see below) or gross dissection, such as the problem of complex crossing and divergent fibres. However, there are some important limitations. Firstly, the high resolution and the complexity of the datasets acquired necessitates high amounts of data storage capacity as well as high performance computers to process the data (Axe, Grassel, et al., 2011). Secondly, data acquisition may be hindered by the fact that, as in gross dissection, brain specimens are also rather scarce. Finally, PLI is an ex-vivo technique and accordingly cannot be translated to a clinical environment. Results from this technique, however, could be used to refine and constrain the algorithms used in diffusion tractography, a technique which does have potential clinical applications.

Diffusion tractography utilises MR diffusion imaging (which maps the direction of water diffusion in each voxel) to infer the pathways and terminations of each tract, in vivo. This method can provide very similar results as gross dissection (Catani, Howard, Pajevic, & Jones, 2002) and is a more flexible technique. It allows both virtual dissections of white matter tracts as well as a method for parcellating the cortex according to the tractographic profile of cortical voxels (Cloutman & Lambon Ralph, 2012). Since it is a computational technique, the data are not destroyed in the analytical process, meaning that it can be independently confirmed by other researchers. The main limitation of tractography is that it is an indirect

measure of white matter. Since white matter pathways are inferred from the diffusion profile of water in the brain, ‘false positive’ and ‘false negative’ results can occur. In addition, there are many different ways to process diffusion data (tensor models, constrained spherical deconvolution, diffusion spectrum) (Haroon, Morris, Embleton, & Parker, 2009; Wedeen, Hagmann, Tseng, Reese, & Weisskoff, 2005), as well as having deterministic (Alexander, 2010) and probabilistic (Parker, Haroon, & Wheeler-Kingshott, 2003) approaches to the tractography itself. Recent evidence has shown that changing the way the data are processed greatly affects the specificity and sensitivity of the method (Thomas et al., 2014).

3. The white matter tracts of the ventral semantic language network

Over the last decade, evidence has grown in support of a dual, rather than single, route model for language processing (Friederici, 2009; Hickok & Poeppel, 2004; Parker et al., 2005; Rauschecker & Scott, 2009; Scott et al., 2000; Ueno et al., 2011). Whilst there are important variations in the details of each theory, there is a general agreement that the dorsal network is associated with phonological processing and the ventral network with semantic aspects of language (Axe, Klingner, & Prescher, 2012; Hickok & Poeppel, 2004; Saur et al., 2008; Ueno & Lambon Ralph, 2013; Ueno et al., 2011). The ventral network comprises a large set of regions spanning all four cerebral lobes (including temporal pole, orbitofrontal cortex, inferior frontal gyrus (IFG), superior parietal lobule (SPL), angular gyrus and the superior, middle and inferior occipital gyri amongst others) that connect with each other

via tracts that course through the temporal lobe (Duffau et al., 2013).

There are four major tracts within the temporal lobe: the uncinate fasciculus (UF), the inferior fronto-occipital fasciculus (IFOF), the middle longitudinal fasciculus (MdLF) and the inferior longitudinal fasciculus (ILF). The original descriptions of these tracts date back to the late 19th century and have been further elaborated by modern neuroscientific studies. While both the UF and ILF have relatively long histories, the MdLF has been scarcely considered until very recently and its potential function remains poorly understood. Additionally, the IFOF has become increasingly popular in the current literature but it is riddled with a debate over its very existence, as is the ILF (Forkel et al., 2014; Schmahmann & Pandya, 2007; Tusa & Ungerleider, 1985). There is also considerable controversy over tract origins, terminations and routes. With the development of modern neuroimaging techniques these old debates have resurfaced. Hence, now is an important time to consider what is known and unknown about the ventral language network. As such, in the following we provide an in depth review of the structure and proposed functional role of each of the four temporal lobe tracts in turn.

3.1. Uncinate fasciculus

The UF was first described by Reil in 1809 and subsequent studies in both human and non-human primates have provided further detail regarding its structure (Catani et al., 2002; Déjerine & Déjerine-Klumpke, 1895; Ebeling & Cramon, 1992; Schmahmann & Pandya, 2009). It is a hook-shaped tract that connects the superior aspect of the temporal pole, anterior entorhinal and perirhinal areas to the basal and lateral portions of the frontal lobe most likely including the pars orbitalis and triangularis of the IFG (Gloor, 1997; Gough, Nobre, & Devlin, 2005; Krestel, Annoni, & Jagella, 2013). The tract takes a curved trajectory, coursing posteriorly through the temporal lobe and then supero-medially into the extreme and external capsules to run below the lentiform nucleus before terminating in the frontal lobe (Burdach, 1822; Schmahmann & Pandya, 2009). Within the extreme capsule (EmC), the UF courses just superior to, and is potentially overlapping with, the IFOF (Gloor, 1997; Trolard, 1906). Indeed, it has been debated whether the fibres of these two tracts intertwine to form one large bundle or whether their fibres are clearly separable (Martino, Brogna, Robles, Vergani, & Duffau, 2010; Nieuwenhuys, Voogd, Voogd, & Huijzen, 2008).

While this anatomical description of the UF has high agreement, there are occasional discrepancies and debates regarding its architecture. For example, while Augusta and Joseph Déjerine described the same classic hook-shaped UF, they also suggested that there is a posterior extension of the UF, resulting in a fanning of the frontal and temporal lobe fibres (Déjerine & Déjerine-Klumpke, 1895). This notion of a posterior UF component has dropped away in modern definitions and it seems possible that the Déjérines may have been describing what is now known to be the IFOF.

Functionally, the association of the UF with key language regions has been highlighted since the time of Carl Wernicke (Eggert, 1977). Due to its connections with temporopolar and inferior frontal regions, the UF has been associated with the

ventral (semantic) language system (Duffau et al., 2013). However, the nature and degree of its role in semantic processing is unclear. Some studies have demonstrated that damage to the UF may result in some degree of semantic processing impairment (Han et al., 2013). Other researchers have found that intraoperative stimulation or resection of the UF fails to elicit semantic errors in picture naming and thus they have argued that, while the UF might be involved in the ventral language pathway, it is not an essential component (Duffau, Gatignol, Moritz-Gasser, & Mandonnet, 2009). On the basis that the UF links frontal (e.g., pars orbitalis) and temporal (anterior temporal regions) areas that are associated with executive control and semantic representation, respectively, some authors have suggested that UF might provide the basis for the executive control of semantic processing (Binney, Parker, & Lambon Ralph, 2012). Instead of conceptualising it as part of the semantic language network, the UF has been commonly delineated as a limbic pathway, connecting regions involved in memory and emotional processing (Fujie et al., 2008; Saur et al., 2008). Indeed, these two proposals are not mutually exclusive given that the two functions might reflect the medial and lateral branches of the UF (Binney et al., 2012).

3.2. Middle longitudinal fasciculus

The MdLF was first described in 1984 by Selzer and Pandya in the macaque (Seltzer & Pandya, 1984) and later in the human by Makris (1999). It connects temporal and parietal regions but, perhaps because of its recent description, is one of the least studied and poorly understood association tracts. Studies to date consistently identify the temporal terminations of the tract as the entire length of the STG up to the dorsal temporal pole, coursing superio-laterally in relation to the IFOF (Makris et al., 2009, 2013; Menjot de Champfleury et al., 2013; Wang et al., 2013). There is less clarity over its parietal terminations. One study found that the human MdLF connects the STG to the angular gyrus (Menjot de Champfleury et al., 2013), while another investigation found that the MdLF continues on to terminate in the SPL (Wang et al., 2013). As a potential explanation to these contradictory findings, a recent large-scale tractography study delineated two bundles within the MdLF: both bundles were found to originate within the STG, with one branch terminating in the angular gyrus and the other in the SPL (Makris et al., 2013). Thus at the posterior end of the temporal lobe, the MdLF passes through the sagittal stratum and then curves upwards through the corona radiata to terminate in both the AG and SPL (Maldonado et al., 2013; Makris et al., 2009, 2013; Menjot de Champfleury et al., 2013; Wang et al., 2013).

The functional significance of the MdLF is unclear. There is no direct evidence correlating the MdLF to any particular cognitive function (Makris et al., 2013), however, some researchers have suggested that, based on its termination in the AG, it may be involved in the language network (Makris et al., 2009; Menjot de Champfleury et al., 2013). Others have speculated more specifically that the MdLF plays a role in both the semantic and phonological language networks (Saur et al., 2010). Evidence from intraoperative electrostimulation has so far failed to show any language impairments, leading some

to conclude that the MdLF may be a non-essential tract within the language network (Hamer, Moritz-Gasser, Gatignol, & Duffau, 2011; Menjot de Champfleury et al., 2013). Recent research has also suggested that rather than being a tract within the semantic system, it may contribute to the ‘where’ pathway of the auditory system (Wang et al., 2013).

3.3. Inferior longitudinal fasciculus

The ILF was first identified by Burdach in 1822 and elaborated upon by the Déjerines (Burdach, 1822; Davis, 1921; Déjerine & Déjerine-Klumpke, 1895; Tusa & Ungerleider, 1985). It has been traditionally described as a long, arched tract that connects the temporal pole, hippocampal formation and inferior temporal gyrus to most of the occipital lobe (see Davis, 1921). In the 19th and early 20th centuries, there was a debate in the anatomical literature as to whether the ILF was indeed an association tract (Burdach, 1822; Davis, 1921; Tusa & Ungerleider, 1985). Tusa and Ungerleider suggested that the ILF was not a single tract but a succession of U-fibres connecting adjacent cortical regions from the occipital lobe down through the inferior temporal gyrus, which they termed the ‘occipito-temporal projection system’ (Tusa & Ungerleider, 1985). However, electrophysiological evidence showed short response latencies in cells from the parahippocampal gyrus and inferior temporal cortex to a visual stimulus (Liu, Agam, Madsen, & Kreiman, 2009; Wilson, Babb, Halgren, & Crandall, 1983), which is consistent with a direct, rather than an indirect, connection between the occipital and anterior temporal lobes (Catani, Jones, Donato, & Ffytche, 2003). In support of both descriptions of the ILF, a recent tractography study delineated both the traditional ILF as described by Burdach, as well as the Tusa and Ungerleider U-fibre occipito-temporal projection system (Catani et al., 2003).

Potential inconsistencies regarding the ILF also exist between human and primate studies. In 1984, Selzar and Pandya described an ILF in the monkey (1984) that, unlike previous human dissections, did not terminate in the occipital lobe, connecting instead to the caudal portion of the IPL. This description was later augmented to include delineation of posterior ILF terminations which contributed fibres to the preoccipital gyrus (Schmahmann & Pandya, 2009) – indicating that there are two ILF branches (one parietal and one occipital). It is currently unclear whether the ILF described in the human and monkey brains have the same trajectory since there is minimal exploration of the parietal branch of the ILF in humans. Indeed, this highlights a fundamental difficulty in the interpretation of tract discrepancies whenever cross-species comparisons are made. Finally, since the parietal terminations of the ILF and the MdLF are very similar (both terminating in the IPL), it is perhaps unclear whether the parietal branch of the ILF and MdLF are indeed two separate tracts or whether they are simply different re-descriptions of the same tract.

In relation to its function, the ILF has been associated with visual perception and semantic processing, while damage to the ILF has been linked with several psychiatric conditions (Catani et al., 2012; Duffau et al., 2013; Shinoura et al., 2007). Given the potential importance of ventrolateral anterior temporal areas in transmodal semantic representation

(Lambon Ralph, 2014; Mion et al., 2010; Peelen & Caramazza, 2012; Shimotake et al., 2014), the ILF – like other connections that converge at the ATL (Binney et al., 2012; Mesulam, 2000; Moran, Mufson, & Mesulam, 1987) – might be critical for fast interactions between the ATL and information/processes rooted in occipital and parietal regions. In respect to other aspects of language processing, recent direct electrical stimulation studies in humans have not elicited naming errors which might imply that the ILF is not a critical pathway for language. However, further research with a variety of methods is required before its possible role(s) in language, if any, can be established (Duffau et al., 2013; Mandonnet, Nouet, Gatignol, Capelle, & Duffau, 2007).

3.4. Inferior fronto-occipital fasciculus

The IFOF, first comprehensively described by Jean Baptist Trolard (1906) and later reproduced by Curran (1909) (c.f. Forkel et al., 2014), is a tract running ventrally through the EmC complex that connects the frontal lobe to the temporal and occipital lobes as well as some parietal regions (Curran, 1909; Martino, Brogna, et al., 2010; Sarubbo, De Benedictis, Maldonado, Basso, & Duffau, 2013; Trolard, 1906). The IFOF appears to be a critical tract for language given that direct stimulation generates semantic paraphasias and deficits in verbal and nonverbal comprehension (Duffau et al., 2005, 2009, 2013).

Many descriptions of the function and anatomical architecture of the IFOF exist within the literature and recently it has been postulated that the tract may be divided into two separate subcomponents (Sarubbo et al., 2013), a superficial/dorsal component and a deeper, more ventral component. The superficial layer connects the IFG to the posterior superior temporal gyrus (STG), the SPL and the superior and middle occipital gyri. The deep layer connects the dorsolateral prefrontal cortex, middle frontal gyrus and orbito-frontal cortex to the posterior middle and inferior temporal cortex, and to the inferior occipital and lingual gyri (Catani et al., 2002; Duffau et al., 2013; Sarubbo et al., 2013). For much of its trajectory in the occipito-temporal region, the IFOF deep component courses close and just superior to the ILF (see below). In the anterior temporal region, the IFOF runs just below the inferior limiting sulcus of the insula and then continues, just superior to the UF, to terminate in the frontal lobe (Duffau et al., 2013; Martino, Brogna, et al., 2010; Martino et al., 2011; Sarubbo et al., 2013).

The IFOF has stimulated considerable debate. Although many studies have documented the presence of this pathway using both gross dissection and tractography methods (Axe et al., 2012; Catani et al., 2002; Forkel et al., 2014; Martino, Brogna, et al., 2010; Sarubbo et al., 2013), based on its absence in primate tracer studies, some researchers have argued that the IFOF is not a true tract but a misidentification of other ventral pathways (Makris & Pandya, 2009; Saur et al., 2008; Schmahmann & Pandya, 2007). However, while there has been no evidence for the existence of the IFOF in primates (Schmahmann & Pandya, 2007), studies have described a primate EmC which tracks from the frontal lobe to posterior regions in the superior temporal sulcus, following a course similar to the IFOF (Schmahmann & Pandya, 2009). In their

tractography study in the human brain, Makris and Pandya (2009) delineated a pathway that resembled the monkey EmC, and identified it as such in the human brain. This 'EmC tract' mirrors that of the IFOF for most of its course (Fernandez-Miranda, Pathak, & Schneider, 2010; Thiebaut de Schotten, Dell'Acqua, Valabregue, & Catani, 2012; Wang et al., 2013). However, while the frontal terminations of the EmC and IFOF are the same, the posterior ones differ. IFOF courses to the occipital lobe while the so called EmC tract terminates in the temporal lobe (Thiebaut de Schotten et al., 2012). An important consideration regarding this debate is the fact that besides differences in inter-species anatomy, monkey studies are able to utilise high resolution tracer techniques that allow the fine-grained differentiation between extreme and external capsules (neither diffusion MRI nor gross dissection has this resolution) (Thiebaut de Schotten et al., 2012). As such, the core of the debate may reflect, in part, a difference in the resolution of the techniques used as well as different uses of terminology to describe the same tract.

3.5. The complex extreme capsule complex

Several zones of white matter are referred to as "capsules"; for example, the internal, external and extreme capsules. Traditionally, capsules are not considered to be neuronal tracts per se, but rather are descriptors of an anatomical location that is composed of several tracts (see Fig. 2) (Axe et al., 2012; Gloor, 1997).

In contrast, the EmC has recently been described as a single tract. Using diffusion imaging in humans, the EmC has been described as an association tract that projects from the inferior parietal lobule to the STG and IFG (Makris & Pandya, 2009). This tract is proposed as an alternative to the IFOF. The trajectories of both tracts are similar but differ in that while the IFOF terminates in the occipital lobe the proposed EmC tract does not, instead having an additional termination in the temporal pole, possibly a conflation of different tracts.

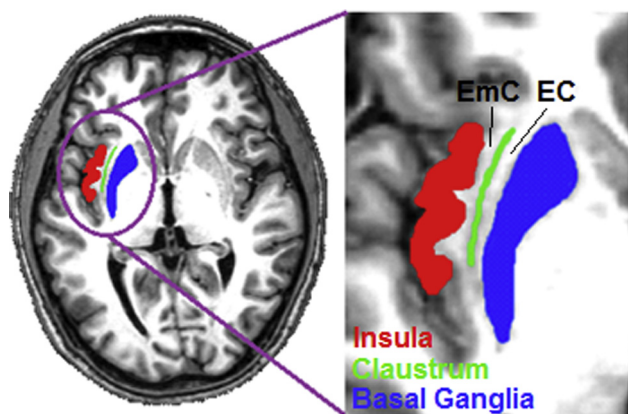


Fig. 2 – Axial MRI scan highlighting the region of the extreme capsule. Red = Insular Cortex; Green = Claustrum; Blue = Putamen. The extreme capsule (EmC) is the region of white matter that is found between the insular cortex and the claustrum. The external capsule (EC) is the region of white matter that is found between the putamen and the claustrum.

4. The dorsal–ventral interaction

While the focus of this review has been on the ventral language pathways, it is only half of the proposed dual-route language network and the 'dorsal-route' has held an important place in the history of the neurobiology of language. As such, to gain a full understanding of the organisation and functioning of the ventral language pathways, it is important to consider them in relation to those of the dorsal network.

The classical 'dorsal-only' neurological model of language was proposed in the 1970s by Norman Geschwind (1970). This model included an input to the auditory cortex, an output from the motor speech areas (proposed to be Broca's area), and an arc of connections between Wernicke's area and Broca's area (allowing for direct repetition of spoken words), liaising with the angular gyrus to license interaction with meaning. These regions are 'dorsally' connected through the most well-known of the 'language' tracts, the AF and the superior longitudinal fasciculus (SLF I–III) (occasionally used synonymously with one another but which are, in fact, different tracts) (Schmahmann & Pandya, 2009). With the development of functional and structural neuroimaging methods, language neuroscientists began to debate and refute the idea that this dorsal route was the only pathway that underpinned human language (Hickok & Poeppel, 2004; Parker et al., 2005; Scott et al., 2000). It became increasingly apparent that while this 'dorsal route' was indeed important for phonological language processing, there was a ventral route which comprised the network underpinning semantic processing (Axe et al., 2012; Hickok & Poeppel, 2004; Saur et al., 2008; Ueno & Lambon Ralph, 2013; Ueno et al., 2011). It is a fact almost lost to history that Wernicke himself not only alluded to a ventral as well as dorsal pathway, but also placed considerable emphasis on the importance of the ventral pathway in language function (Eggert, 1977; Weiller et al., 2011). Consequently, within modern conceptualisations of the dual dorsal-ventral language network, such as those proposed by Ueno et al. (2011) and Bornkessel-Schlesewsky and colleagues (Bornkessel-Schlesewsky & Schlesewsky, 2013; Bornkessel-Schlesewsky et al., 2015), there is a division of labour between the ventral pathway which is involved in time-invariant sound-to-meaning mappings, and the dorsal pathway involved in time-variant sound-to-motor mappings.

In addition to exploring the functional-computational differences in each pathway, these models also suggest that the two pathways interact (both in normal function and even more after recovery post damage) to support a range of language activities. Yet, how the two processing pathways interact is a matter which has been little explored empirically, both anatomically and functionally [see Cloutman (2013) for a review]. There is strong evidence for the necessity and existence of a close interaction between the dorsal and ventral streams in the successful execution of linguistic skills. For example, semantic dementia patients' atrophy is centred on the anterior temporal region and seems to be confined entirely to the ventral pathway. As expected from the division of labour between the two pathways, the patients present with a selective multimodal semantic impairment but preserved single word and nonword repetition. However, once the

phonological system is taxed more heavily (e.g., in delayed or multi-item repetition) the patients begin to generate phoneme migration errors particularly for those words that have the most impoverished meaning (Jefferies, Crisp, & Lambon Ralph, 2006; Jefferies, Hoffman, Jones, & Lambon Ralph, 2008; Patterson, Graham, & Hodges, 1994). Such phenomena are not limited to the pathological language system; semantic effects are observed in normal single word repetition when there is intrinsically high phonological competition (Tyler, Voice, & Moss, 2000; Ueno et al., 2014) or when repetition is made more challenging [mixed word-nonword lists (Jefferies, Frankish, & Lambon Ralph, 2006)]. Patterson, Jefferies and colleagues have suggested that semantics help to constrain or bind a word's constituent phonological elements together (Jefferies, Frankish, et al., 2006; Patterson et al., 1994). Although the neural basis of these effects was not considered in these previous studies, they would seem to suggest that there are important interactions between the dorsal and ventral pathways; yet where, when, and how these occur is still unknown. Thus the interconnection and interaction between the dorsal and ventral language networks within the brain is an important area for future exploration.

5. The need for a white matter 'lingua franca'

Despite the increased interest in the brain's white matter, there is still inconsistency in the terminology used for different tracts, which probably reflects three sources. First, most of the classical neuroanatomical literature was written in German and French (c.f. Déjerine & Dejerine-Klumpke, 1895; Onufrowicz, 1887) and the original texts can be hard to find, thus increasing the reliance on secondary sources. Translational variations and misinterpretations have inevitably led to different labelling of identical anatomical structures which tends to perpetuate misunderstanding. Likewise, important information may have been lost over time; for example, Weiller and colleagues have hypothesised that Wernicke's own identification of a ventral as well as dorsal language pathway may have been missed by Geschwind due to a translation-related misunderstanding (Weiller et al., 2011). Secondly, both human and non-human neuroanatomical investigations provide key sources of information yet they often use different labelling conventions and, inevitably, there are uncertainties in cross-species homology (Gloor, 1997).

Thirdly, neuroanatomy is a highly descriptive subject. Its development relies on having a consistent and unambiguous 'lingua franca' which the field can use. Despite this, white matter pathways in the brain are variably referred to as tract, pathway, fascicle, fasciculus, lemniscus and capsule, and many of these labels are ill-defined in the literature. For example, many groups consider a capsule (e.g., the EmC) to be an area of white matter which is formed by several tracts (Duffau et al., 2013; Martino, Vergani, Robles, & Duffau, 2010). On the other hand, other groups have argued that a capsule can itself be a single fibre bundle (Saur et al., 2008, 2010; Schmahmann & Pandya, 2007). There are also occasions where, although meaning is clear, terminology is used inconsistently [e.g., inferior fronto-occipital fasciculus (Martino, Brogna, et al., 2010; Sarubbo et al., 2013;

Schmahmann & Pandya, 2007), versus occipitofrontal fasciculus (Kier, Staib, Davis, & Bronen, 2004; Makris et al., 2007)]. While there has been a concerted international effort amongst anatomists to streamline anatomical terminology via the Terminologia Anatomica ("Terminologia Anatomica," 1998), the neuroscience anatomical literature has remained riddled with inconsistencies. Clearly a larger participation of neuroscientists towards the acceptance of a comprehensive and universally-adopted terminological framework would be beneficial to the field.

6. Conclusion

Both the classic and contemporary literature have posited a ventral language pathway that passes through temporal lobe areas. Since this time, various methods have been used to map the white matter pathways that may underpin language function. Dissection and MR tractography continue to provide sophisticated descriptions of the location and branches of the four major fasciculi that course through the temporal lobe (UF, MdLF, IFOF and ILF). In comparison, the exact nature of their functional contribution to language processing is less well developed. To date, all four have been primarily implicated in various semantic aspects of language though the MdLF might play important roles in auditory and phonological processing. Additional investigations are needed to provide greater detail on the functional role(s) of these key white matter pathways.

Acknowledgements

CJB was supported by a DTP studentship from the BBSRC (BB/J014478/1). This research was supported by was supported by an MRC programme grant to MALR (MR/J004146/1).

Appendix. Glossary

EC: External capsule. An area of white matter between the claustrum and the putamen (basal ganglia). Due to poor resolution, the EC is rarely distinguishable from the extreme capsule when using diffusion MRI.

EmC: Extreme capsule. Some studies refer to the extreme capsule as a white matter tract while others use it as a descriptor for an area of white matter between the insula and the claustrum. Due to poor resolution, the EmC is rarely distinguishable from the EC when using diffusion MRI.

IFG: Inferior frontal gyrus. The inferior most gyrus in the frontal lobe, situated just superiorly to the sylvian fissure. From anterior to posterior it is comprised of the pars orbitalis, pars triangularis and pars opercularis. The latter two subdivisions form Broca's area.

IFOF: Inferior fronto-occipital fasciculus. A long white matter tract that connects the occipital lobe to the frontal lobe. There is a controversy in the literature over its existence.

ILF: Inferior longitudinal fasciculus. A long white matter tract that connects the occipital lobe to the temporal lobe. There is a controversy in the literature over its existence.

MdLF: Middle longitudinal fasciculus. A long white matter tract that connects the parietal lobe to the superior temporal gyrus. The precise terminations of the tract are still unclear.

STG: Superior temporal gyrus. The superior most gyrus in the temporal lobe. It is situated just inferior to the sylvian fissure.

UF: Uncinate fasciculus. A hook shaped white matter tract that connects the temporal pole to the frontal lobe.

REFERENCES

- Acosta-Cabronero, J., Patterson, K., Fryer, T. D., Hodges, J. R., Pengas, G., Williams, G. B., et al. (2011). Atrophy, hypometabolism and white matter abnormalities in semantic dementia tell a coherent story. *Brain*, 134, 2025–2035. <http://dx.doi.org/10.1093/Brain/Awr119>.
- Aghajani, M., Veer, I. M., van Lang, N. D., Meens, P. H., van den Bulk, B. G., Rombouts, S. A., et al. (2013). Altered white-matter architecture in treatment-naïve adolescents with clinical depression. *Psychological Medicine*, 1–12. <http://dx.doi.org/10.1017/S0033291713003000>.
- Agrawal, A., Kapfhammer, J. P., Kress, A., Wichers, H., Deep, A., Feindel, W., et al. (2011). Josef Klingler's models of white matter tracts: influences on neuroanatomy, neurosurgery, and neuroimaging. *Neurosurgery*, 69(2), 238–252. <http://dx.doi.org/10.1227/NEU.0b013e318214ab79>. discussion 252–234.
- Alexander, A. L. (2010). Deterministic White matter tractography. In D. K. Jones (Ed.), *Diffusion MRI: Theory, methods, and applications* (pp. 383–395). USA: Oxford University Press.
- Axer, M., Amunts, K., Grassel, D., Palm, C., Dammers, J., Axer, H., et al. (2011). A novel approach to the human connectome: ultra-high resolution mapping of fiber tracts in the brain. *NeuroImage*, 54(2), 1091–1101. <http://dx.doi.org/10.1016/j.neuroimage.2010.08.075>.
- Axer, M., Grassel, D., Kleiner, M., Dammers, J., Dickscheid, T., Reckfort, J., et al. (2011). High-resolution fiber tract reconstruction in the human brain by means of three-dimensional polarized light imaging. *Frontiers in Neuroinformatics*, 5, 34. <http://dx.doi.org/10.3389/fninf.2011.00034>.
- Axer, H., Klingner, C. M., & Prescher, A. (2012). Fiber anatomy of dorsal and ventral language streams. *Brain and Language*. <http://dx.doi.org/10.1016/j.bandl.2012.04.015>.
- Bagga, D., Sharma, A., Kumari, A., Kaur, P., Bhattacharya, D., Garg, M. L., et al. (2013). Decreased white matter integrity in fronto-occipital fasciculus bundles: relation to visual information processing in alcohol-dependent subjects. *Alcohol*. <http://dx.doi.org/10.1016/j.alcohol.2013.10.009>.
- Binney, R. J., Parker, G. J. M., & Lambon Ralph, M. A. (2012). Convergent connectivity and Graded Specialization in the rostral human temporal lobe as Revealed by diffusion-Weighted imaging probabilistic tractography. *Journal of Cognitive Neuroscience*, 24(10), 1998–2014.
- Bornkessel-Schlesewsky, I., & Schlesewsky, M. (2013). Reconciling time, space and function: a new dorsal-ventral stream model of sentence comprehension (Research Support, Non-U.S. Gov't) *Brain and Language*, 125(1), 60–76. <http://dx.doi.org/10.1016/j.bandl.2013.01.010>.
- Bornkessel-Schlesewsky, I., Schlesewsky, M., Small, S. L., & Rauschecker, J. P. (2015). Neurobiological roots of language in primate audition: common computational properties (Review) *Trends in Cognitive Sciences*. <http://dx.doi.org/10.1016/j.tics.2014.12.008>.
- Burdach, K. F. (1822). In J. D. Schmahmann, & D. Pandya (Eds.), *Vom Baue und Leben des Gehirns*. Leipzig: Dyk'schen Buchhandlung.
- Butler, R. A., Lambon Ralph, M. A., & Woollams, A. M. (2014). Capturing multidimensionality in stroke aphasia: mapping principal behavioural components to neural structures. *Brain*, 137(Pt 12), 3248–3266. <http://dx.doi.org/10.1093/brain/awu286>.
- Catani, M., Dell'acqua, F., Bizzi, A., Forkel, S. J., Williams, S. C., Simmons, A., et al. (2012). Beyond cortical localization in clinico-anatomical correlation. *Cortex*, 48(10), 1262–1287. <http://dx.doi.org/10.1016/j.cortex.2012.07.001>.
- Catani, M., Howard, R. J., Pajevic, S., & Jones, D. K. (2002). Virtual in vivo Interactive dissection of white matter fasciculi in the human brain. *NeuroImage*, 17(1), 77–94. <http://dx.doi.org/10.1006/nimg.2002.1136>.
- Catani, M., Jones, D. K., Donato, R., & Ffytche, D. H. (2003). Occipito-temporal connections in the human brain. *Brain*, 126(Pt 9), 2093–2107. <http://dx.doi.org/10.1093/brain/awg203>.
- Cloutman, L. L. (2013). Interaction between dorsal and ventral processing streams: where, when and how? *Brain and Language*, 127(2), 251–263. <http://dx.doi.org/10.1016/j.bandl.2012.08.003>.
- Cloutman, L. L., & Lambon Ralph, M. A. (2012). Connectivity-based structural and functional parcellation of the human cortex using diffusion imaging and tractography. *Frontiers in Neuroanatomy*, 6, 34. <http://dx.doi.org/10.3389/fnana.2012.00034>.
- Curran, E. J. (1909). A new association fiber tract in the cerebrum with remarks on the fiber tract dissection method of studying the brain. *Journal of Comparative Neurology and Psychology*, 19(6), 645–656. <http://dx.doi.org/10.1002/cne.920190603>.
- Davis, L. E. (1921). An anatomic study of the inferior longitudinal fasciculus. *Archives of Neurology & Psychiatry*, 5(4), 370–381. <http://dx.doi.org/10.1001/archneurpsyc.1921.02180280011002>.
- Déjerine, J. J., & Déjerine-Klumpke, A. (1895). In J. D. Schmahmann, & D. N. Pandya (Eds.), *Anatomie des centres nerveux*. Paris: Rueff.
- Duffau, H., Gatignol, P., Mandonnet, E., Peruzzi, P., Tzourio-Mazoyer, N., & Capelle, L. (2005). New insights into the anatomo-functional connectivity of the semantic system: a study using cortico-subcortical electrostimulations. *Brain*, 128, 797–810. <http://dx.doi.org/10.1093/Brain/Awh423>.
- Duffau, H., Gatignol, P., Moritz-Gasser, S., & Mandonnet, E. (2009). Is the left uncinate fasciculus essential for language? *Journal of Neurology*, 256(3), 382–389. <http://dx.doi.org/10.1007/s00415-009-0053-9>.
- Duffau, H., Herbet, G., & Moritz-Gasser, S. (2013). Toward a pluricomponent, multimodal, and dynamic organization of the ventral semantic stream in humans: lessons from stimulation mapping in awake patients. *Frontiers in Systems Neuroscience*, 7, 44. <http://dx.doi.org/10.3389/fnsys.2013.00044>.
- Ebeling, U., & Cramon, D. V. (1992). Topography of the uncinate fascicle and adjacent temporal fiber tracts. *Acta Neurochirurgica*, 115(3–4), 143–148. <http://dx.doi.org/10.1007/bf01406373>.
- Eggert, G. H. (1977). *Wernicke's works on aphasia: A sourcebook and review*. Mouton.
- Fernandez-Miranda, J. C., Pathak, S., & Schneider, W. (2010). High-definition fiber tractography and language. *Journal of Neurosurgery*, 113(1), 156–157. <http://dx.doi.org/10.3171/2009.10.JNS091460>. author reply 157–158.
- Forkel, S. J., Thiebaut de Schotten, M., Kawadler, J. M., Dell'acqua, F., Danek, A., & Catani, M. (2014). The anatomy of fronto-occipital connections from early blunt dissections to contemporary tractography. *Cortex*, 56, 73–84.
- Fridriksson, J., Kjartansson, O., Morgan, P. S., Hjaltason, H., Magnusdottir, S., Bonilha, L., et al. (2010). Impaired speech repetition and left parietal lobe damage [Research Support,

- N.I.H., Extramural] *The Journal of Neuroscience*, 30(33), 11057–11061. <http://dx.doi.org/10.1523/JNEUROSCI.1120-10.2010>.
- Friederici, A. D. (2009). Pathways to language: fiber tracts in the human brain [Review] *Trends in Cognitive Sciences*, 13(4), 175–181. <http://dx.doi.org/10.1016/j.tics.2009.01.001>.
- Fujie, S., Namiki, C., Nishi, H., Yamada, M., Miyata, J., Sakata, D., et al. (2008). The role of the uncinate fasciculus in memory and emotional recognition in amnesic mild cognitive impairment. *Dementia and Geriatric Cognitive Disorders*, 26(5), 432–439. <http://dx.doi.org/10.1159/000165381>.
- Fujino, J., Takahashi, H., Miyata, J., Sugihara, G., Kubota, M., Sasamoto, A., et al. (2014). Impaired empathic abilities and reduced white matter integrity in schizophrenia. *Progress In Neuro-Psychopharmacology & Biological Psychiatry*, 48, 117–123. <http://dx.doi.org/10.1016/j.pnpbp.2013.09.018>.
- Geschwind, N. (1970). The organization of language and the brain. *Science*, 170(3961), 940–944.
- Gloor, P. (1997). *The temporal lobe and limbic system*. Oxford University Press.
- Gough, P. M., Nobre, A. C., & Devlin, J. T. (2005). Dissociating linguistic processes in the left inferior frontal cortex with transcranial magnetic stimulation. *The Journal of Neuroscience*, 25(35), 8010–8016. <http://dx.doi.org/10.1523/jneurosci.2307-05.2005>.
- Hamer, P. C. D. W., Moritz-Gasser, S., Gatignol, P., & Duffau, H. (2011). Is the human left middle longitudinal fascicle essential for language? A brain electrostimulation study. *Human Brain Mapping*, 32(6), 962–973. <http://dx.doi.org/10.1002/Hbm.21082>.
- Han, Z., Ma, Y., Gong, G., He, Y., Caramazza, A., & Bi, Y. (2013). White matter structural connectivity underlying semantic processing: evidence from brain damaged patients. *Brain*. <http://dx.doi.org/10.1093/brain/awt205>.
- Haroon, H. A., Morris, D. M., Embleton, K. V., & Parker, G. J. (2009). *Model based residual bootstrap of constrained spherical deconvolution for probabilistic segmentation and tractography*. Paper presented at the Proceedings of the 17th Scientific Meeting and Exhibition of the International Society for Magnetic Resonance in Medicine, Honolulu, Hawaii, USA.
- Harvey, D. Y., Wei, T., Ellmore, T. M., Hamilton, A. C., & Schnur, T. T. (2013). Neuropsychological evidence for the functional role of the uncinate fasciculus in semantic control. *Neuropsychologia*, 51(5), 789–801. <http://dx.doi.org/10.1016/j.neuropsychologia.2013.01.028>.
- Hickok, G., & Poeppel, D. (2004). Dorsal and ventral streams: a framework for understanding aspects of the functional anatomy of language. *Cognition*, 92(1–2), 67–99. <http://dx.doi.org/10.1016/j.cognition.2003.10.011>.
- Hickok, G., & Poeppel, D. (2007). Opinion – The cortical organization of speech processing. *Nature Reviews Neuroscience*, 8(5), 393–402. <http://dx.doi.org/10.1038/Nrn2113>.
- Holland, R., & Lambon Ralph, M. A. (2010). The anterior temporal lobe semantic hub is a part of the language neural network: selective disruption of irregular past tense verbs by rTMS. *Cerebral Cortex*, 20(12), 2771–2775. <http://dx.doi.org/10.1093/cercor/bhq020>.
- Jefferies, E., Crisp, J., & Lambon Ralph, M. A. (2006). The impact of phonological or semantic impairment on delayed auditory repetition: evidence from stroke aphasia and semantic dementia. *Aphasiology*, 20(9–11), 963–992. <http://dx.doi.org/10.1080/02687030600739398>.
- Jefferies, E., Frankish, C. R., & Lambon Ralph, M. A. (2006). Lexical and semantic binding in verbal short-term memory. *Journal of Memory and Language*, 54(1), 81–98. <http://dx.doi.org/10.1016/j.jml.2005.08.001>.
- Jefferies, E., Hoffman, P., Jones, R., & Lambon Ralph, M. A. (2008). The impact of semantic impairment on verbal short-term memory in stroke aphasia and semantic dementia: a comparative study. *Journal of Memory and Language*, 58(1), 66–87. <http://dx.doi.org/10.1016/j.jml.2007.06.004>.
- Kier, E. L., Staib, L. H., Davis, L. M., & Bronen, R. A. (2004). MR imaging of the temporal stem: anatomic dissection tractography of the uncinate fasciculus, inferior occipitofrontal fasciculus, and Meyer's loop of the optic radiation. *American Journal of Neuroradiology*, 25(5), 677–691.
- Krestel, H., Annoni, J. M., & Jagella, C. (2013). White matter in aphasia: a historical review of the Dejerines' studies. *Brain and Language*. <http://dx.doi.org/10.1016/j.bandl.2013.05.019>.
- Lambon Ralph, M. A. (2014). Neurocognitive insights on conceptual knowledge and its breakdown. *Philosophical Transactions of the Royal Society B: Biological Sciences*, 369(1634), 20120392. <http://dx.doi.org/10.1098/rstb.2012.0392>.
- Larsen, L., Griffin, L. D., Grassel, D., Witte, O. W., & Axer, H. (2007). Polarized light imaging of white matter architecture. *Microscopy Research and Technique*, 70(10), 851–863. <http://dx.doi.org/10.1002/jemt.20488>.
- Liu, H., Agam, Y., Madsen, J. R., & Kreiman, G. (2009). Timing, timing, timing: fast decoding of object information from intracranial field potentials in human visual cortex. *Neuron*, 62(2), 281–290. <http://dx.doi.org/10.1016/j.neuron.2009.02.025>.
- Liu, X. Y., Lai, Y. Y., Wang, X. J., Hao, C. X., Chen, L., Zhou, Z. Y., et al. (2013). Reduced white matter integrity and cognitive deficit in never-medicated chronic schizophrenia: a diffusion tensor study using TBSS. *Behavioural Brain Research*, 252, 157–163. <http://dx.doi.org/10.1016/j.bbr.2013.05.061>.
- Ludwig, E., & Klingler, J. (1956). *Atlas Cerebri Humani: The inner structure of the brain demonstrated on the basis of macroscopical preparations*. Boston: Little, Brown and Company.
- Makris, N. (1999). *Delineation of human association fiber pathways using histologic and magnetic resonance methodologies* (PhD PhD). Boston, MA: Boston University. Retrieved from <http://www.cma.mgh.harvard.edu/staff/nm/Makris-PhD-THESIS.pdf>.
- Makris, N., & Pandya, D. N. (2009). The extreme capsule in humans and rethinking of the language circuitry. *Brain Structure and Function*, 213(3), 343–358. <http://dx.doi.org/10.1007/s00429-008-0199-8>.
- Makris, N., Papadimitriou, G. M., Kaiser, J. R., Sorg, S., Kennedy, D. N., & Pandya, D. N. (2009). Delineation of the middle longitudinal fascicle in humans: a quantitative, in vivo, DT-MRI study. *Cerebral Cortex*, 19(4), 777–785. <http://dx.doi.org/10.1093/cercor/bhn124>.
- Makris, N., Papadimitriou, G. M., Sorg, S., Kennedy, D. N., Caviness, V. S., & Pandya, D. N. (2007). The occipitofrontal fascicle in humans: a quantitative, in vivo, DT-MRI study. *NeuroImage*, 37(4), 1100–1111. <http://dx.doi.org/10.1016/j.neuroimage.2007.05.042>.
- Makris, N., Preti, M. G., Wassermann, D., Rath, Y., Papadimitriou, G. M., Yerganian, C., et al. (2013). Human middle longitudinal fascicle: segregation and behavioral-clinical implications of two distinct fiber connections linking temporal pole and superior temporal gyrus with the angular gyrus or superior parietal lobule using multi-tensor tractography. *Brain Imaging and Behavior*, 7(3), 335–352. <http://dx.doi.org/10.1007/s11682-013-9235-2>.
- Maldonado, I. L., de Champfleury, N. M., Velut, S., Destrieux, C., Zemmoura, I., & Duffau, H. (2013). Evidence of a middle longitudinal fascicle in the human brain from fiber dissection. *Journal of Anatomy*, 223(1), 38–45. <http://dx.doi.org/10.1111/joa.12055>.
- Mandonnet, E., Nouet, A., Gatignol, P., Capelle, L., & Duffau, H. (2007). Does the left inferior longitudinal fasciculus play a role in language? A brain stimulation study. *Brain*, 130, 623–629. <http://dx.doi.org/10.1093/Brain/Awl361>.
- Martino, J., Brogna, C., Robles, S. G., Vergani, F., & Duffau, H. (2010). Anatomic dissection of the inferior fronto-occipital

- fasciculus revisited in the lights of brain stimulation data. *Cortex*, 46(5), 691–699. <http://dx.doi.org/10.1016/j.cortex.2009.07.015>.
- Martino, J., De Witt Hamer, P. C., Vergani, F., Brogna, C., de Lucas, E. M., Vazquez-Barquero, A., et al. (2011). Cortex-sparing fiber dissection: an improved method for the study of white matter anatomy in the human brain. *Journal of Anatomy*, 219(4), 531–541. <http://dx.doi.org/10.1111/j.1469-7580.2011.01414.x>.
- Martino, J., Vergani, F., Robles, S. G., & Duffau, H. (2010). New insights into the anatomic dissection of the temporal stem with special emphasis on the inferior fronto-occipital fasciculus: implications in surgical approach to left mesiotemporal and temporoinular structures. *Neurosurgery*, 66(3), 4–12. <http://dx.doi.org/10.1227/01.Neu.0000348564.28415.Fa>.
- Menjot de Champfleury, N., Lima Maldonado, I., Moritz-Gasser, S., Machi, P., Le Bars, E., Bonafe, A., et al. (2013). Middle longitudinal fasciculus delineation within language pathways: a diffusion tensor imaging study in human. *European Journal of Radiology*, 82(1), 151–157. <http://dx.doi.org/10.1016/j.ejrad.2012.05.034>.
- Mesulam, M. M. (2000). *Principles of behavioral and cognitive neurology*. USA: Oxford University Press.
- Mion, M., Patterson, K., Acosta-Cabrero, J., Pengas, G., Izquierdo-Garcia, D., Hong, Y. T., et al. (2010). What the left and right anterior fusiform gyri tell us about semantic memory. *Brain*, 133, 3256–3268. <http://dx.doi.org/10.1093/Brain/Awq272>.
- Moran, M. A., Mufson, E. J., & Mesulam, M. M. (1987). Neural inputs into the temporopolar cortex of the Rhesus-monkey. *Journal of Comparative Neurology*, 256(1), 88–103. <http://dx.doi.org/10.1002/cne.902560108>.
- Nieuwenhuys, R., Voogd, J., Voogd, J., & Huijzen, C. v (2008). *The human central nervous system*. Springer.
- Onufrowicz, W. (1887). Das balkenlose Mikrocephalengehirn Hofmann. [The acallosal microcephalic brain Hofmann. A contribution to the pathological and normal anatomy of the human brain.]. *Archiv für Psychiatrie und Nervenkrankheiten*, 18(2), 305–328. <http://dx.doi.org/10.1007/bf02054370>.
- Parker, G. J. M., Haroon, H. A., & Wheeler-Kingshott, C. A. M. (2003). A framework for a streamline-based probabilistic index of connectivity (PICO) using a structural interpretation of MRI diffusion measurements. *Journal of Magnetic Resonance Imaging*, 18(2), 242–254. <http://dx.doi.org/10.1002/jmri.10350>.
- Parker, G. J. M., Luzzi, S., Alexander, D. C., Wheeler-Kingshott, C. A. M., Ciccarelli, O., & Lambon Ralph, M. A. (2005). Lateralization of ventral and dorsal auditory-language pathways in the human brain. *NeuroImage*, 24(3), 656–666. <http://dx.doi.org/10.1016/j.neuroimage.2004.08.047>.
- Patterson, K., Graham, N., & Hodges, J. R. (1994). The impact of semantic memory Loss on phonological representations. *Journal of Cognitive Neuroscience*, 6(1), 57–69. <http://dx.doi.org/10.1162/jocn.1994.6.1.57>.
- Patterson, K., & Lambon Ralph, M. A. (1999). Selective disorders of reading? *Current Opinion in Neurobiology*, 9(2), 235–239. [http://dx.doi.org/10.1016/S0959-4388\(99\)80033-6](http://dx.doi.org/10.1016/S0959-4388(99)80033-6).
- Peelen, M. V., & Caramazza, A. (2012). Conceptual object representations in human anterior temporal cortex. *The Journal of Neuroscience*, 32(45), 15728–15736. <http://dx.doi.org/10.1523/jneurosci.1953-12.2012>.
- Pobric, G., Jefferies, E., & Lambon Ralph, M. A. (2007). Anterior temporal lobes mediate semantic representation: Mimicking semantic dementia by using rTMS in normal participants. *Proceedings of the National Academy of Sciences of the United States of America*, 104(50), 20137–20141. <http://dx.doi.org/10.1073/pnas.0707383104>.
- Rauschecker, J. P., & Scott, S. K. (2009). Maps and streams in the auditory cortex: nonhuman primates illuminate human speech processing. *Nature Neuroscience*, 12(6), 718–724. <http://dx.doi.org/10.1038/nn.2331>.
- Rubinov, M., & Sporns, O. (2010). Complex network measures of brain connectivity: uses and interpretations. *NeuroImage*, 52(3), 1059–1069. <http://dx.doi.org/10.1016/j.neuroimage.2009.10.003>.
- Sarubbo, S., De Benedictis, A., Maldonado, I. L., Basso, G., & Duffau, H. (2013). Frontal terminations for the inferior fronto-occipital fascicle: anatomical dissection, DTI study and functional considerations on a multi-component bundle. *Brain Structure and Function*, 218(1), 21–37. <http://dx.doi.org/10.1007/s00429-011-0372-3>.
- Saur, D., Kreher, B. W., Schnell, S., Kummerer, D., Kellmeyer, P., Vry, M. S., et al. (2008). Ventral and dorsal pathways for language. *Proceedings of the National Academy of Sciences of the United States of America*, 105(46), 18035–18040. <http://dx.doi.org/10.1073/pnas.0805234105>.
- Saur, D., Schelter, B., Schnell, S., Kratochvil, D., Kupper, H., Kellmeyer, P., et al. (2010). Combining functional and anatomical connectivity reveals brain networks for auditory language comprehension. *NeuroImage*, 49(4), 3187–3197. <http://dx.doi.org/10.1016/j.neuroimage.2009.11.009>.
- Schmahmann, J. D., & Pandya, D. N. (2007). The complex history of the fronto-occipital fasciculus. *Journal of the History of the Neurosciences*, 16(4), 362–377. <http://dx.doi.org/10.1080/09647040600620468>.
- Schmahmann, J. D., & Pandya, D. (2009). *Fiber pathways of the brain*. Oxford University Press.
- Scott, S. K., Blank, C. C., Rosen, S., & Wise, R. J. S. (2000). Identification of a pathway for intelligible speech in the left temporal lobe. *Brain*, 123(12), 2400–2406. <http://dx.doi.org/10.1093/brain/123.12.2400>.
- Seltzer, B., & Pandya, D. N. (1984). Further observations on parieto-temporal connections in the Rhesus-monkey. *Experimental Brain Research*, 55(2), 301–312.
- Shimotake, A., Matsuomoto, R., Ueno, T., Kunieda, T., Saito, S., Hoffman, P., et al. (2014). Direct exploration of the role of the ventral anterior temporal lobe in semantic memory: cortical stimulation and local field potential evidence from subdural grid electrodes. *Cerebral Cortex*. <http://dx.doi.org/10.1093/cercor/bhu262> (Epub ahead of print).
- Shinoura, N., Suzuki, Y., Tsukada, M., Katsuki, S., Yamada, R., Tabei, Y., et al. (2007). Impairment of inferior longitudinal fasciculus plays a role in visual memory disturbance. *Neurocase*, 13(2), 127–130. <http://dx.doi.org/10.1080/13554790701399254>.
- Sporns, O. (2013). Structure and function of complex brain networks. *Dialogues in Clinical Neuroscience*, 15(3), 247–262.
- Terminologia Anatomica. (1998). from <http://www.unifr.ch/ifaa/>.
- Thiebaut de Schotten, M., Dell'Acqua, F., Valabregue, R., & Catani, M. (2012). Monkey to human comparative anatomy of the frontal lobe association tracts. *Cortex*, 48(1), 82–96. <http://dx.doi.org/10.1016/j.cortex.2011.10.001>.
- Thomas, C., Ye, F. Q., Irfanoglu, M. O., Modi, P., Saleem, K. S., Leopold, D. A., et al. (2014). Anatomical accuracy of brain connections derived from diffusion MRI tractography is inherently limited. *Proceedings of the National Academy of Sciences of the United States of America*, 111(46), 16574–16579. <http://dx.doi.org/10.1073/pnas.1405672111>.
- Trolard, J. B. (1906). Le faisceau longitudinal inferieur du cerveau. *Revue Neurologique*, 14, 440–446.
- Tusa, R. J., & Ungerleider, L. G. (1985). The inferior longitudinal fasciculus: a reexamination in humans and monkeys. *Annals of Neurology*, 18(5), 583–591. <http://dx.doi.org/10.1002/ana.410180512>.
- Tyler, L. K., Voice, J. K., & Moss, H. E. (2000). The interaction of meaning and sound in spoken word recognition. *Psychonomic*

- Bulletin & Review, 7(2), 320–326. <http://dx.doi.org/10.3758/Bf03212988>.
- Ueno, T., & Lambon Ralph, M. A. (2013). The roles of the “ventral” semantic and “dorsal” pathways in conduite d’approche: a neuroanatomically-constrained computational modeling investigation. *Frontiers in Human Neuroscience*, 7, 422. <http://dx.doi.org/10.3389/fnhum.2013.00422>.
- Ueno, T., Saito, S., Rogers, T. T., & Lambon Ralph, M. A. (2011). Lichtheim 2: synthesizing aphasia and the neural basis of language in a neurocomputational model of the dual dorsal-ventral language pathways [Research Support, Non-U.S. Gov’t] *Neuron*, 72(2), 385–396. <http://dx.doi.org/10.1016/j.neuron.2011.09.013>.
- Ueno, T., Saito, S., Saito, A., Tanida, Y., Patterson, K., & Lambon Ralph, M. A. (2014). Not lost in translation: generalization of the primary systems hypothesis to Japanese-specific language processes. *Journal of Cognitive Neuroscience*, 26(2), 433–446. http://dx.doi.org/10.1162/jocn_a_00467.
- Wang, Y. B., Fernandez-Miranda, J. C., Verstynen, T., Pathak, S., Schneider, W., & Yeh, F. C. (2013). Rethinking the role of the middle longitudinal fascicle in language and auditory pathways. *Cerebral Cortex*, 23(10), 2347–2356. <http://dx.doi.org/10.1093/cercor/bhs225>.
- Wedeen, V. J., Hagmann, P., Tseng, W. Y. I., Reese, T. G., & Weisskoff, R. M. (2005). Mapping complex tissue architecture with diffusion spectrum magnetic resonance imaging. *Magnetic Resonance in Medicine*, 54(6), 1377–1386. <http://dx.doi.org/10.1002/Mrm.20642>.
- Weiller, C., Bormann, T., Saur, D., Musso, M., & Rijntjes, M. (2011). How the ventral pathway got lost – And what its recovery might mean. *Brain and Language*, 118(1–2), 29–39. <http://dx.doi.org/10.1016/j.bandl.2011.01.005>.
- Williamson, J. B., Heilman, K. M., Porges, E. C., Lamb, D. G., & Porges, S. W. (2013). A possible mechanism for PTSD symptoms in patients with traumatic brain injury: central autonomic network disruption [Review] *Frontiers in Neuroengineering*, 6, 13. <http://dx.doi.org/10.3389/fneng.2013.00013>.
- Wilson, C. L., Babb, T. L., Halgren, E., & Crandall, P. H. (1983). Visual receptive fields and response properties of neurons in human temporal lobe and visual pathways. *Brain*, 106(Pt 2), 473–502.